CHEST®

Official publication of the American College of Chest Physicians

Lung Development and Adult Lung Diseases

Wei Shi, Saverio Bellusci and David Warburton

Chest 2007;132;651-656
DOI 10.1378/chest.06-2663

The online version of this article, along with updated information and services can be found online on the World Wide Web at:
http://chestjournal.org/cgi/content/abstract/132/2/651

CHEST is the official journal of the American College of Chest Physicians. It has been published monthly since 1935. Copyright 2007 by the American College of Chest Physicians, 3300 Dundee Road, Northbrook IL 60062. All rights reserved. No part of this article or PDF may be reproduced or distributed without the prior written permission of the copyright holder (http://www.chestjournal.org/misc/reprints.shtml). ISSN: 0012-3692.

AMERICAN COLLEGE OF CHEST PHYSICIANS®

Downloaded from chestjournal.org on August 20, 2007
Copyright © 2007 by American College of Chest Physicians

CHEST Translating Basic Research Into Clinical Practice

Lung Development and Adult Lung Diseases*

Wei Shi, MD, PhD; Saverio Bellusci, PhD; and David Warburton, DSc, MD

Adult respiratory diseases are caused by many factors, including genetic-environmental interaction. Genetic abnormalities can impact early fetal lung development, postnatal lung maturation, as well as adult lung injury and repair. Studies suggest that abnormally developed lung structure and function may contribute as a susceptibility factor for several adult lung diseases. This review focuses on the relationship between lung development and pathogenesis of several lung diseases including COPD, cystic fibrosis (CF), and asthma. COPD with emphysema has been considered to be an accelerated involutional disease of aging smokers. However, since only a proportion (approximately 15%) of smokers get COPD with emphysema, clearly genetic susceptibility must play a significant part in determining both the age of onset and the rapidity of decline in lung function. In mice, interference with key genes either by null mutation, hypomorphism, or gain or loss of function results in phenotypes comprising either neonatal lethal respiratory distress if the structural effect is severe, or reduced alveolarization and/or early onset emphysema if the effect is milder. Reported susceptibility candidate genes are therefore discussed in some detail, including elastin, lysyl oxidase, fibrillin, the transforming growth factor-β-Smad3 pathway, as well as extracellular matrix proteases. In the case of CF, the *Cftr* gene has been shown to regulate fetal lung epithelial cell differentiation and maturation. Subtle abnormalities of lung structure and function are found in clinically asymptomatic CF infants. Finally, airway remodeling due to chronic inflammation is important in infants who later acquire asthma. ***(CHEST 2007; 132:651–656)***

Key words: adult lung disease; asthma; COPD; cystic fibrosis; genetic susceptibility; lung development

Abbreviations: CF = cystic fibrosis; CFTR = cystic fibrosis transmembrane regulator; FGF = fibroblast growth factor; MMP = matrix metaloproteinase; TGF = transforming growth factor

The complex process of mammalian lung development includes lung airway branching morphogenesis and alveolarization, together with angiogenesis and vasculogenesis. Severe defects of any of these developmental events will lead to neonatal respiratory failure and death in infants. However, the impact of milder structural or functional defects, occurring as a result of aberrant lung development, have been neglected in the past due to a relative lack of early respiratory symptoms, plus the technical difficulties of making an anatomic or physiologic diagnosis *in vivo*. Accumulated data obtained as a result of significant advancements in human genomic studies and rodent genetic manipulation indicate that early abnormal lung development may indeed be a significant susceptibility factor in certain respiratory diseases that become clinically detectable during childhood or even during later life, such as COPD, cystic fibrosis (CF), and asthma.

Lung Development

The lung arises from the floor of the primitive foregut as the laryngotracheal groove at approximately

*From the Developmental Biology Program, Saban Research Institute, Childrens Hospital Los Angeles, Keck School of Medicine and School of Dentistry, University of Southern California, Los Angeles, CA.
The authors have no conflicts of interest to disclose.
Manuscript received October 31, 2006; revision accepted January 18, 2007.
Reproduction of this article is prohibited without written permission from the American College of Chest Physicians (www.chestjournal.org/misc/reprints.shtml).
Correspondence to: David Warburton, DSc, MD, Developmental Biology Program, Saban Research Institute, Children's Hospital Los Angeles, 4650 Sunset Blvd MS35, Los Angeles, CA 90027; e-mail: DWarburton@chla.usc.edu
DOI: 10.1378/chest.06-2663

Downloaded from chestjournal.org on August 20, 2007
Copyright © 2007 by American College of Chest Physicians

4 to 6 weeks gestation in humans (Fig 1). The proximal portion of this primitive structure gives rise to the larynx and trachea, which becomes separated from the esophagus, while progenitor cells located at the distal part of the primitive trachea give rise to the left and right main stem bronchi. Branching morphogenesis of the left and right bronchi forms specific lobar, segmental, and lobular branches. This process extends through the canalicular stage of lung development up to approximately 20 weeks gestation in humans. The first 16 of these 23 airway generations are stereo specific in humans, the remainder being fractal in geometry, but with a distinct proximal-distal pattern of diameter and epithelial differentiation that are genetically "hard wired." Alveolarization begins at approximately 20 weeks in humans and continues at least up to 7 years of age, giving rise to an eventual alveolar gas diffusion surface 70 m^2 in area by 1 μm in thickness. This enormous surface is closely apposed to an alveolar capillary network capable of accommodating a blood flow between 5 L/min at rest and 25 L/min at maximal oxygen consumption in the young and fit adult. The entire developmental process of the lung is orchestrated by finely integrated and mutually regulated networks of transcriptional factors, growth factors, matrix components, and physical forces.[1–3] Factors that adversely impact the developing lung include human prematurity, oxygen exposure, early corticosteroid exposure, incorrect amounts of growth factor (platelet-derived growth factor, fibroblast growth factor [FGF],

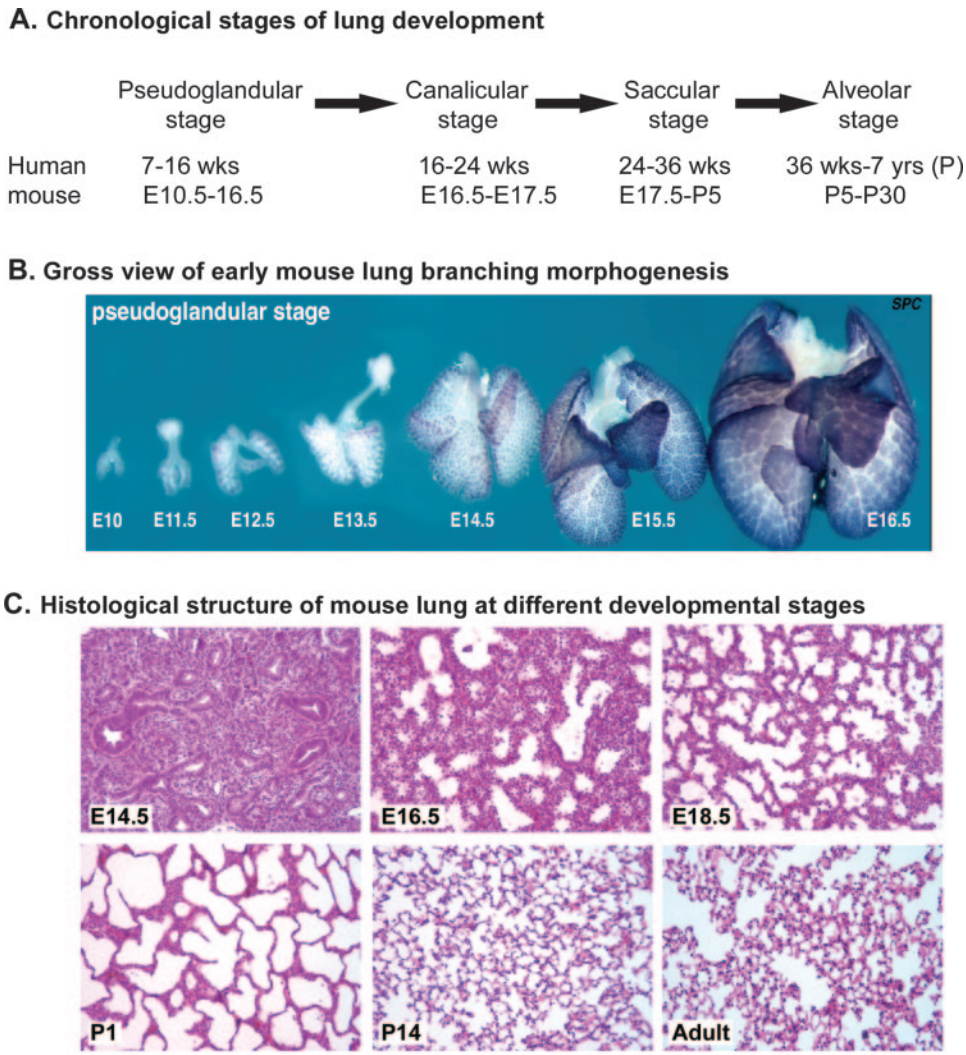

FIGURE 1. Lung developmental chronology. *Top*, *A*: The timing of lung developmental stages in human and mice. Human gestational stage is presented in weeks (wks), while mouse embryonic stage (E) is presented in days. P indicates postnatal age in weeks. *Center*, *B*: Expression of *Sp-C* by whole-mount *in situ* hybridization in a developmental series of early embryonic lung branching morphogenesis. *Bottom*, *C*: Histologic structures of developing lungs at different stages are shown by hematoxylin-eosin–stained lung tissue sections (original × 200).

Downloaded from chestjournal.org on August 20, 2007
Copyright © 2007 by American College of Chest Physicians

vascular endothelial growth factor, transforming growth factor [TGF]-β family, and Wnt) signaling, abnormal regulation, or injury of the pulmonary capillary vasculature. Individually and cumulatively, these all result in hypoplasia of the alveolar epithelial surface, with a resulting deficiency in gas transport, particularly during exercise. For example, survivors of human prematurity with bronchopulmonary dysplasia will desaturate on maximal exercise during childhood, and some are now entering young adulthood with increasingly severe gas diffusion problems.

In addition, physical forces play an important role in regulating lung formation. *In utero*, the lung is a hydraulic, fluid-filled system. Secretion of fluid into the airway lumen is osmotically driven by active chloride secretion through chloride channels. This gives rise to a continuous forward flow of lung liquid that drains into the amniotic fluid. The larynx acts as a hydraulic pinchcock valve and maintains an intraluminal hydraulic pressure of approximately 1.5 cm water in the airways. Excess fluid drainage during fetal life results in hypoplasia of the lung. Conversely, obstruction of the trachea in embryonic lung in culture can result in a doubling of the rate of airway branching. Moreover, physiologic fluctuations in intraluminal pressure caused by coordinated peristaltic contractions of airway smooth muscle have been shown to play an important role in embryonic lung branching morphogenesis,[4] while fetal breathing movements causes cyclic fluctuation of intratracheal pressure during fetal life. Following cord clamping and the resulting rush of catecholamines at birth, the lung lumen dries out and rapidly switches to air breathing. Clearance of lung intraluminal liquid is mediated by cessation of chloride secretion into the lumen and activation of active sodium transport out of the lumen. Null mutation of sodium transporter channel genes (*α-epithelial sodium channel, α-EnaC*) is neonatal lethal because it abrogates this net osmotically driven fluid uptake. "Erection" of alveolar septa is relatively poorly understood. Nevertheless, correct organization of elastin matrix niche is important, as is remodeling of the alveolar capillary network. This suggests that vascular hydraulic perfusion pressure may play a key role in the emergence of septal structures into the alveolar space. This concept is further supported by a requirement for vascular endothelial growth factor secretion by the alveolar epithelium to maintain vascular integrity and remodeling, and hence correct epithelial branching as well as alveolar morphogenesis.[5,6]

Lung Development and COPD

At the other end of the developmental spectrum, namely during aging, progressive involution of alveolar gas diffusion capacity occurs over the last decades of life, which may be accelerated by exposure to adverse environmental factors such as tobacco smoke, inhaled particulates, smog, industrial pollutants, toxic inhalants, infectious agents, and so forth. In industrialized societies where these risk factors are present, there is presently an epidemic of pulmonary failure due to COPD, which is now the fourth-leading cause of adult death in the United States. COPD with emphysema has hitherto been considered to be an accelerated, involutional disease of aging smokers. However, since only a certain proportion (approximately 15%) of smokers get COPD with emphysema, clearly genetic susceptibility must play a significant part. Recently, we have begun to wonder whether developmental issues may underlie at least some susceptibility to apparently adult-onset chronic lung disease. Certainly the increasing numbers of survivors of human prematurity may be at special risk. However, there may be other more subtle developmental genetic issues of concern.

Pulmonary emphysema is classified as a major component of COPD. The pathology of emphysema has been characterized as loss of respiratory surface area, as evidenced by abnormal, permanent enlargement of airspaces distal to the terminal bronchioles.[7] These pathologic changes result in dramatic reduction of respiratory function in COPD patients. Etiologically, emphysema is thought to be caused by many genetic factors, in combination with environmentally harmful factors. In mice, interference with many key genes either by null mutation, hypomorphism, or gain or loss of function results in final common phenotypes comprising either neonatal lethal respiratory distress if the structural effect is severe, or reduced alveolarization and early onset emphysema if the effect is milder. For example, *Fgf10* as well as *Fgfr2b* null mutation completely abrogate lung branching morphogenesis distal to the carina, whereas hypomorphic or ectopic FGF signaling results in neonatal lethal alveolar dysplasia. This demonstrates that correct and indeed very finely regulated FGF signaling is absolutely required for lung morphogenesis distal to the carina, as well as for correct progress of all subsequent stages of lung development up to and including alveolarization.[2]

Null mutation of *Smad3,* which is a key receptor-activated Smad in the TGF-β signaling pathway, results initially in a rather subtle failure of correct organization of the matrix, which in turn is an antecedent of subsequent, early onset but still relatively mild pulmonary emphysema.[8] This early onset emphysema in *Smad3* null mutants is also associated with activation of excessive matrix metaloproteinase (MMP) activity. Thus, correct organization of the

Downloaded from chestjournal.org on August 20, 2007
Copyright © 2007 by American College of Chest Physicians

matrix during alveolarization may protect against subsequent proteolytic degradation and deterioration of the matrix, with subsequent loss of functional alveolar gas diffusion surface. We have also found that exposure to side stream smoke profoundly exacerbates and accelerates alveolar destruction in young *Smad3* null mice (unpublished results).

This work thus provides further support for the concept that failure of correct matrix organization may predispose to certain serious degenerative lung diseases; conversely, correct matrix organization may be protective against these same degenerative diseases. Therefore, deficient TGF-β-Smad3–mediated regulation may be an antecedent of COPD by multiple mechanisms (Fig 2). Moreover, polymorphisms of fibrillin-1, latent TGF-β–binding protein 4 in the TGF-β pathway and MMP genes have been described in humans with emphysema[9–11]; as well as mutations in endoglin, a proteoglycan that modulates signaling functions in the TGF-β pathway and is responsible for pulmonary telangiectasia.[12] In contrast, excessive expression of the bone morphogenetic protein 4 growth factor inhibitor gremlin has been described in idiopathic pulmonary fibrosis.[13]

Correct formation of the alveolar elastin niche and hence elastic interdependence are essential for normal lung structure and function during development. In the lung, normal deposition and arrangement of elastin fibers is particularly important in the formation and maintenance of alveolar crests. For example, in young mice with the *Elastin* null mutation, alveolar crests fail to form.[14] Null mutation of lysyl oxidase prevents correct elastin cross-linking, and hence alveolarization is also incomplete.[15] Similarly, in mice with the *Pdgf-a* null mutation, alveolar myofibroblasts fail to differentiate and produce elastin; hence, alveolar crests also fail to form.[16] Whereas in mice with the *Fgfr3/Fgfr4* double null mutation excessive, dysmorphic elastin is laid down, which also disrupts the formation of alveolar crests.[17] Failure to protect elastin from proteolytic degradation in α_1-antitrypsin deficiency,[18] or from excessive destruction of elastin mediated by neutrophil elastase induced by chronic cigarette smoke exposure, results in the disease termed *emphysema*, which is characterized by destruction of the alveolar walls.

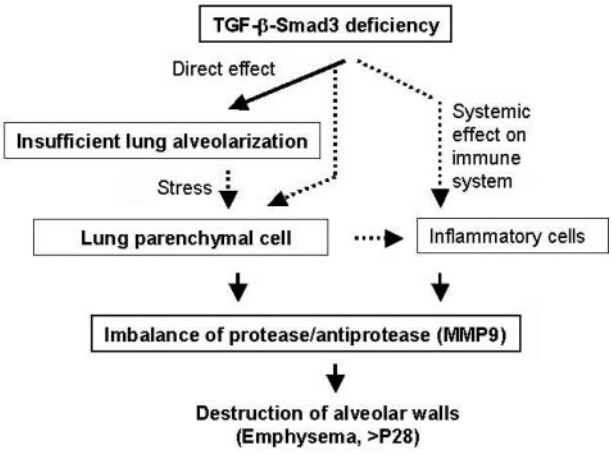

FIGURE 2. Concept diagram explaining the proposed sequence of events in Smad3 null mutant mice leading to early onset centrilobular emphysema. Defective Smad3 results in abnormal lung alveolarization. The subsequent imbalanced protease/antiprotease activities, such as MMP-9, may arise from several possible mechanisms, as indicated by arrows with dotted line. P28 = postnatal day 28.

Elastic interdependence of the lung is an important concept in respiratory physiology, which accounts for orderly elastic recoil of the lungs during passive expiration. At the alveolar level, elastic interdependence is mediated by the correct expression, cross-linking, and orientation of elastin and collagen fibers. Thus, absence of correctly cross-linked and oriented elastin containing matrix predisposes to failure of correct establishment of elastic interdependence and alveolarization, while excessive degradation of elastin containing matrix underlies loss of elastic interdependence and alveolar degeneration.

One quite novel way of interpreting the results discussed above is that dysplastic or degraded matrix can provide neither the structural niche nor the environmental cues for alveolar stem/progenitor cells to assume the correct phenotype and/or repair the correct alveolar cell lineage matrix niche. As an example, up or down dysregulation at several critical points in the TGF-β pathway results in pulmonary pathobiologic outcomes that can be interpreted in this light: null mutation of TGF-β_1 results in lethal lung inflammation; excessive TGF-β_1 expression results in alveolar hypoplasia (bronchopulmonary dysplasia) in the neonate vs fibrosis in the adult. The hope is that by protecting the alveolar progenitor cell population with small soluble molecules and/or providing the correct exogenous signals, alveolar progenitor cells can be preserved to maintain or repair the alveolar gas diffusion surface.[19,20] Since children still possess the inherent capacity to grow new lung alveolar tissue at least up to age 7 years, it is to be hoped that preserving or replacing the regenerative capacity of their alveolar progenitor cells will be practicable. However, in COPD this will likely prove to be much more challenging since large areas of alveolar surface are destroyed, leaving only isolated islands of intact tissue. The hope here is that these isolated areas of relatively normal tissue progenitors may be retained or can be seeded with sufficient exogenous progenitors to optimize alveolar regeneration.

Downloaded from chestjournal.org on August 20, 2007
Copyright © 2007 by American College of Chest Physicians

Lung Development and Other Common Lung Diseases

CF is a genetic disease with mutations in a gene called CF transmembrane regulator (CFTR), which encodes an epithelial chloride channel. Despite its pleiotropic nature, lung disease is a major clinical manifestation for CF patients. The severity of CF lung disease differs depending on which of several loss-of-function mutations has been recessively inherited. Traditionally, CF lung was considered to be normal at birth, and to undergo progressive postnatal damage by recurrent infection and inflammation. However, studies[21–24] on *Cftr* gene function in lung development in mice and examination of clinically asymptomatic infants with *CFTR* mutations indicate that in fact CFTR may be involved not only in lung epithelial differentiation and functional maturation during developmental stages, but also in contributing to CF lung disease postnatally. For example, approximately one fourth of asymptomatic CF infants, whose respiratory status was considered normal by pulmonologists, were found to have reduced airflow using a more sensitive pulmonary function test comprising a raised volume rapid thoracoabdominal compression technique.[21] Moreover, by high-resolution CT, Long et al[22] found that the airways of infants and young children with CF are dilated with thicker walls. In addition, tracheal epithelium in CF fetuses at gestation 19 to 23 weeks was found to be either atrophic or metaplastic and devoid of microvilli,[23] which does not bode well for prenatal or postnatal mucus clearance. Moreover, lung small airway grafted from human CF fetuses into mice with severe combined immune deficiency underwent more rapid neutrophil-mediated inflammation and tissue destruction, even in these severely immune deficient mice, which lack natural killer cells, suggesting that CF lung inflammation may arise at least partly from a primary defect in the lung epithelium, independent of infection.[24]

Asthma is another chronic inflammatory airway disease, characterized by intermittent airway obstruction that causes difficulty in breathing. The airway obstruction is mediated by hyperresponsive bronchial smooth muscle, edema, and mucus secretion from inflamed airway wall. Studies[25,26] have indicated that airway inflammation and remodeling already exist in infants who will subsequently acquire asthma, suggesting that pathologic defects in asthma occur very early in life before the development of symptoms. It is assumed that the fetal structures have never fully matured in these children. In addition, whether abnormal differentiation of lung smooth-muscle cells and myofibroblasts during fetal lung development result in postnatal hyperresponsive and hypertrophic bronchial smooth-muscle cell layer in asthma patients remains unexplored. We have discovered that differentiation of airway smooth muscle in the embryonic lung is controlled by FGF, bone morphogenetic protein, and sonic hedgehog signaling,[23,26] which supports the concept that developmental events will affect lung function later on in life.

What Can We Do About It?

Certainly, passive exposure to smoke during intrauterine as well as extrauterine lung development has long been recognized to predispose children to having poor respiratory health in general, as well as an increased incidence of sudden infant death syndrome.[27–30] However the postulate that genetic-developmental defects such as CF as well as other perhaps more subtle genetic susceptibilities may worsen the effects of passive smoking in childhood and of smoking *per se* in early adulthood has received less attention. We suggest here that adverse environmental factors such as passive smoking or pollution from freeway traffic are not good for growing lungs.[31] This is particularly true if the embryo, fetus, child, teen, or young adult has the bad luck to have abnormally developed lungs or is genetically susceptible to having an impaired response to lung injury or repair. Therefore, one of the simplest things we (parents and society) can do to reduce the burden of adult-onset lung disease is work to eliminate passive smoking either *in utero* or postnatally during early lung development, as well as active smoking by children and young persons. Further work to better characterize and appreciate genetic and other susceptibility factors that predispose children to getting apparently adult-onset lung disease, and conversely to protecting against it will also be important. In many cases, lung failure does not just arise in adults "out of the blue."

References

1 Warburton D, Schwarz M, Tefft D, et al. The molecular basis of lung morphogenesis. Mech Dev 2000; 92:55–81

2 Warburton D, Bellusci S, De Langhe S, et al. Molecular mechanisms of early lung specification and branching morphogenesis. Pediatr Res 2005; 57:26R–37R

3 Warburton D, Bellusci S, Del Moral PM, et al. Growth factor signaling in lung morphogenetic centers: automaticity, stereotypy and symmetry. Respir Res 2003; 4:5

4 Jesudason EC, Smith NP, Connell MG, et al. Developing rat lung has a sided pacemaker region for morphogenesis-related airway peristalsis. Am J Respir Cell Mol Biol 2005; 32:118–127

5 Warburton D, Shi W. Lo, and the niche is knit: lysyl oxidase activity and maintenance of lung, aorta, and skin integrity.

Downloaded from chestjournal.org on August 20, 2007
Copyright © 2007 by American College of Chest Physicians

Am J Pathol 2005; 167:921–922
6 Del Moral PM, Sala FG, Tefft D, et al. VEGF-A signaling through Flk-1 is a critical facilitator of early embryonic lung epithelial to endothelial crosstalk and branching morphogenesis. Dev Biol 2006; 290:177–188
7 Snider GL, Kleinerman J, Thurlbeck WM, et al. The definition of emphysema: report of a National Heart, Lung, and Blood Institute, Division of Lung Diseases Workshop. Am Rev Respir Dis 1985; 132:182–185
8 Chen H, Sun J, Buckley S, et al. Abnormal mouse lung alveolarization caused by Smad3 deficiency is a developmental antecedent of centrilobular emphysema. Am J Physiol Lung Cell Mol Physiol 2005; 288:L683–L691
9 Kaartinen V, Warburton D. Fibrillin controls TGF-β activation. Nat Genet 2003; 33:331–332
10 Hersh CP, Demeo DL, Lazarus R, et al. Genetic association analysis of functional impairment in chronic obstructive pulmonary disease. Am J Respir Crit Care Med 2006; 173: 977–984
11 Joos L, He JQ, Shepherdson MB, et al. The role of matrix metalloproteinase polymorphisms in the rate of decline in lung function. Hum Mol Genet 2002; 11:569–576
12 McAllister KA, Grogg KM, Johnson DW, et al. Endoglin, a TGF-β binding protein of endothelial cells, is the gene for hereditary haemorrhagic telangiectasia type 1. Nat Genet 1994; 8:345–351
13 Koli K, Myllarniemi M, Vuorinen K, et al. Bone morphogenetic protein-4 inhibitor gremlin is overexpressed in idiopathic pulmonary fibrosis. Am J Pathol 2006; 169:61–71
14 Wendel DP, Taylor DG, Albertine KH, et al. Impaired distal airway development in mice lacking elastin. Am J Respir Cell Mol Biol 2000; 23:320–326
15 Maki JM, Sormunen R, Lippo S, et al. Lysyl oxidase is essential for normal development and function of the respiratory system and for the integrity of elastic and collagen fibers in various tissues. Am J Pathol 2005; 167:927–936
16 Bostrom H, Willetts K, Pekny M, et al. PDGF-A signaling is a critical event in lung alveolar myofibroblast development and alveogenesis. Cell 1996; 85:863–873
17 Weinstein M, Xu X, Ohyama K, et al. FGFR-3 and FGFR-4 function cooperatively to direct alveogenesis in the murine lung. Development 1998; 125:3615–3623
18 Churg A, Wright JL. Proteases and emphysema. Curr Opin Pulm Med 2005; 11:153–159
19 Weiss DJ, Berberich MA, Borok Z, et al. Adult stem cells, lung biology, and lung disease: NHLBI/Cystic Fibrosis Foundation Workshop. Proc Am Thorac Soc 2006; 3:193–207
20 Warburton D, Berberich MA, Driscoll B. Stem/progenitor cells in lung morphogenesis, repair, and regeneration. Curr Top Dev Biol 2004; 64:1–16
21 Ranganathan SC, Bush A, Dezateux C, et al. Relative ability of full and partial forced expiratory maneuvers to identify diminished airway function in infants with cystic fibrosis. Am J Respir Crit Care Med 2002; 166:1350–1357
22 Long FR, Williams RS, Castile RG. Structural airway abnormalities in infants and young children with cystic fibrosis. J Pediatr 2004; 144:154–161
23 De Langhe S, Carraro G, Warburton D, et al. Levels of mesenchymal FGFR2 signaling modulate smooth muscle progenitor cell commitment in the lung. Dev Biol 2006: 52–62
24 Ornoy A, Arnon J, Katznelson D, et al. Pathological confirmation of cystic fibrosis in the fetus following prenatal diagnosis. Am J Med Genet 1987; 28:935–947
25 Tirouvanziam R, Khazaal I, Peault B. Primary inflammation in human cystic fibrosis small airways. Am J Physiol Lung Cell Mol Physiol 2002; 283:L445–L451
26 Bousquet J, Yssel H, Vignola AM. Is allergic asthma associated with delayed fetal maturation or the persistence of conserved fetal genes? Allergy 2000; 55:1194–1197
27 Mailleux AA, Kelly R, Veltmaat JM, et al. Fgf10 expression identifies parabronchial smooth muscle cell progenitors and is required for their entry into the smooth muscle lineage. Development 2005; 132:2157–2166
28 Strachan DP, Cook DG. Health effects of passive smoking. 1. Parental smoking and lower respiratory illness in infancy and early childhood. Thorax 1997; 52:905–914
29 Cook DG, Starchan DP. Health effects of passive smoking: 10. Summary of effects of parental smoking on the respiratory health of chilldren and implications for research. Thorax 1999; 54:357–366
30 Tong FK, England L, Glantz SA. Changing conclusions on secondhand smoke in a sudden infant death syndrome review funded by the tobacco industry. Pediatrics 2005; 115:e355–e366
31 Gauderman WJ, Vora H, McConnell R, et al. Effect of exposure to traffic on lung development from 10 to 18 years of age: a cohort study. Lancet 2007; 369:571–577

Downloaded from chestjournal.org on August 20, 2007
Copyright © 2007 by American College of Chest Physicians

Lung Development and Adult Lung Diseases
Wei Shi, Saverio Bellusci and David Warburton
Chest 2007;132;651-656
DOI 10.1378/chest.06-2663

This information is current as of August 20, 2007

Updated Information & Services	Updated information and services, including high-resolution figures, can be found at: http://chestjournal.org/cgi/content/full/132/2/651
References	This article cites 30 articles, 15 of which you can access for free at: http://chestjournal.org/cgi/content/full/132/2/651#BIBL
Permissions & Licensing	Information about reproducing this article in parts (figures, tables) or in its entirety can be found online at: http://chestjournal.org/misc/reprints.shtml
Reprints	Information about ordering reprints can be found online: http://chestjournal.org/misc/reprints.shtml
Email alerting service	Receive free email alerts when new articles cite this article sign up in the box at the top right corner of the online article.
Images in PowerPoint format	Figures that appear in CHEST articles can be downloaded for teaching purposes in PowerPoint slide format. See any online article figure for directions.

AMERICAN COLLEGE OF
CHEST
PHYSICIANS®

Downloaded from chestjournal.org on August 20, 2007
Copyright © 2007 by American College of Chest Physicians